

## THE IMPORTANCE OF VOLUMETRY, LYMPHSCINTIGRAPHY AND COMPUTER TOMOGRAPHY IN THE DIAGNOSIS OF BRACHIAL EDEMA AFTER MASTECTOMY

E. Göltner, P. Gass, J.P. Haas, P. Schneider

Department of Gynecology and Obstetrics and the Department of Radiology, Städtische Kliniken, Lehrkrankenhaus, Fulda, West Germany

### ABSTRACT

Arm volumes of 360 patients with breast cancer were determined by a new optoelectronic technique. About 42% developed swelling of the arm after modified radical mastectomy which varied from mild (edema-volume 150-400ml), moderate (400-800ml), to severe (more than 800ml) lymphatic edema. Lymphoscintigraphy and computer tomography of the arms was also studied in different grades of lymphatic edema.

Two years after operation and telecobalt-irradiation, one half of the patients without arm edema showed marked signs of a decreased capacity of lymphatic transport. In patients with severe lymphatic edema, the dynamic as well as the static evaluation of the lymphoscintigrams revealed delayed transport, lack of radioisotope accumulation in the axillary region and notable congestion in the upper arm and forearm. Computerized tomography displayed a shift of fluid volume in the epifascial and subfascial tissue compartments and detected progressive structural changes in the soft tissue. Moderate edema not only increased the epifascial but also the subfascial compartments. In severe postmastectomy arm lymphedema, however, expansion of the epifascial space was paradoxically sometimes associated with a decrease in the subfascial compartment.

A common complication of treatment of carcinoma of the breast is swelling of the arm. The following report summarizes our experience with three new diagnostic methods for identifying and assessing brachial edema after mastectomy: optoelectronic volumetry, lymphoscintigraphy and computer tomography.

### MATERIALS AND METHODS

This study includes 120 women (average age of 58.5 years), with Stage I-III breast cancer (T1-3, NO-2, MO; right breast 58, left 62). The volume of the arm was measured in each patient using optoelectronic volumetry before surgery (modified radical mastectomy), using the method devised by Fischbach and Göltner (3,6). The measurement was repeated between the 10th and 14th day of the postoperative period. Between 5 and 35 lymph nodes were removed at operation. Pathological investigation (Prof. Dr. R. Bässler, Pathologisches Institut der Städt. Kliniken Fulda) revealed that the carcinoma had invaded the axilla in 68 patients (56.7%). After excision, 2 drains were positioned in the axilla. These were removed between the 4th and 8th postoperative day when the wound secretions had ceased to be bloody and were minimal.

Brachial volume determinations were carried out in 40 patients (average age 56

### Reproducibility Determinations

1 arm, 25 measurements with arm in fixed position

1 arm, 25 measurements with arm repositioned

1 arm, repositioned and measured by 25 persons

100 arms of 50 healthy persons  
21 years 167.3cm/60kg

Area measured: 400 cm<sup>2</sup>

years), with carcinoma of the breast (T2-3, N1-2, MO; right breast 21) before, during and after follow-up radiotherapy. Radiotherapy began approximately 2 weeks after mastectomy. Tangential irradiation of the chest wall with 50 Gy and irradiation of the lymph drainage of the axilla with 60 Gy was in 25-30 sessions (Radiologisches Institut der Städt. Kliniken Fulda, J.P. Haas).

The brachial volume was determined optoelectronically in 40 patients undergoing posttumor follow-up (average age 55.1 years; 99, left 101) on average 19.3 months after modified radical mastectomy up to telecobalt irradiation. Preoperative postoperative brachial volume determinations were available.

We also assessed the brachial volume and performed isotopic determinations of the lymphatic system of the arms on the untreated sides in a further 40 patients using the method described (2,10,11). 1mCi Tc-99m-labeled albumin in the nanocolloid form was injected into the second intercostal space of both hands and the clearance was monitored over the right and left arm with a field camera. Dynamic curves were calculated to determine the arrival time of the percent storage activity in the region for 1 hour and the retention of the colloid at the

**Table 1**  
**Reproducibility of Arm Volume Measurements**  
**Determined by Optoelectronic Volumetry\***

1 arm, 25 measurements with arm in fixed device	1670 ± 4.6ml - ± 0.28%
1 arm, 25 measurements with arm repositioned each time	1675 ± 8.9ml - ± 0.53%
1 arm, repositioned each time measured by 25 persons	1673 ± 9.5ml - ± 0.62%
100 arms of 50 healthy persons 21 years 167.3cm/60.1kg	1472 ± 133.0ml

\*Area measured: 40cm proximal from the ulnar styloid process.

years), with carcinoma of the breast (T2-3, N1-2, MO; right breast 19, left 21) before, during and after telecobalt follow-up radiotherapy. Radiotherapy began approximately 2 weeks after mastectomy. Tangential irradiation of the chest wall with 50 Gy and stationary irradiation of the lymph drainage system of the axilla with 60 Gy was performed in 25-30 sessions (Radiologisches Institut der Städt. Kliniken Fulda, Prof. Dr. J.P. Haas).

The brachial volume was also determined optoelectronically in 200 patients undergoing posttumor follow-up treatment (average age 55.1 years; right breast 99, left 101) on average 19.3 months after modified radical mastectomy and follow-up telecobalt irradiation. Preoperative and postoperative brachial volumes were not available.

We also assessed the brachial volume and performed isotopic scintigraphic determinations of the lymph system of the arms on the treated and untreated sides in a further 54 patients using the method described by Weissleder (2,10,11). 1mCi Tc-99m-labeled human albumin in the nanocolloid form was injected into the second interdigital space in both hands and the clearance of the colloid over the right and left axilla was monitored for one hour with a large-field camera. Dynamic curves were used to calculate the arrival time of the tracer, the percent storage activity of the axillary region for 1 hour and the percent retention of the colloid at the injection site

after 4 hours. The lymph drainage conditions in both arms were also recorded in static pictures, enabling qualitative as well as quantitative determination of the lymphscintigraphy.

Computer tomography (Somatom DR 3, Siemens, Erlangen) was also used to assess the epifascial and subfascial volume distribution in volumetrically-determined postmastectomy brachial edema of differing degrees of severity in a further 12 patients. This study was done by comparing the computer tomograms taken 16cm above and 8cm below the olecranon process on the treated and contralateral side.

## RESULTS

### Volumetry

Because traditional measurement of brachial volume with water displacement and tape measure are time consuming and imprecise, we developed an automated optoelectronic method. Reliable results are achieved rapidly with this method (measuring time 1 second) (3). The system evaluates the shadow of the arm using microprocessors.

Table 1 displays that the reproducibility of the values for the healthy arm is about 0.5%. This method, therefore, can be used to assess continually changes in arm volume during the treatment of carcinoma of the breast and compare the values with those of the healthy side. If the arm volume increases between 150 and 400 ml, edema is considered slight.

## Y, PUTER OF CTOMY

partment of Radiology,  
Germany

1 complication of treat-  
ma of the breast is swell-  
1. The following report  
- experience with three  
methods for identifying  
brachial edema after mas-  
electronic volumetry,  
y and computer tomo-

## IND METHODS

7 includes 120 women  
58.5 years), with Stage I-  
r (T1-3, NO-2, MO;  
left 62). The volume of  
easured in each patient  
ronic volumetry before  
ed radical mastectomy),  
od devised by Fischbach  
6). The measurement was  
the 10th and 14th day of  
e period. Between 5 and  
were removed at opera-  
cal investigation (Prof.  
, Pathologisches Institut  
iken Fulda) revealed that  
ad invaded the axilla in  
.7%). After excision, 2  
sitioned in the axilla.  
oved between the 4th and  
e day when the wound  
ceased to be bloody and

lume determinations were  
0 patients (average age 56

**Table 2**  
**Incidence of Brachial Edema after Modified  
Radical Mastectomy and Telecobalt Irradiation**

Edema	Before Surgery [n = 120]	10-14 Days After Surgery [n = 120]	Immediately after Surgery and Irradiation [n = 40]	19.3 Months after Surgery and Irradiation [n = 200]
Slight 150 - 400ml	0	12%	35%	25%
Moderate 400 - 800ml	0	0	10%	10%
Severe Above 800ml	0	0	0	7%
<b>TOTAL</b>	0	12%	45%	42%

Increases between 400 and 800 ml, and more than 800 ml indicate moderate and severe edema respectively.

Pre- and postoperative brachial volumes were determined optoelectronically in 120 patients with carcinoma of the breast and summarized in *Table 2*. Two weeks after modified radical mastectomy, slight brachial edema was determined in 12% of the women. At the end of radiation treatment, 45% of the women had increases in brachial volume of more than 150ml, 35% having slight, and 10% moderate edema. Forty-two percent of the patients undergoing posttumor follow-up treatment had brachial edema (moderate to severe lymphostasis in 17%).

The patients undergoing radiation therapy were divided into two groups according to the changes in arm volume and the results are shown in *Fig. 1*. The left side of the figure shows women with values in the normal range ( $\pm 150$ ml). Even in these women, a statistically significant increase in arm volume of 73ml was determined during irradiation.

The arm volume in the patients in the right of *Fig. 1* increased much more during irradiation and values exceeded the normal range. Slight subsidence of swelling was observed in only a few patients.

#### Lymphoscintigraphy

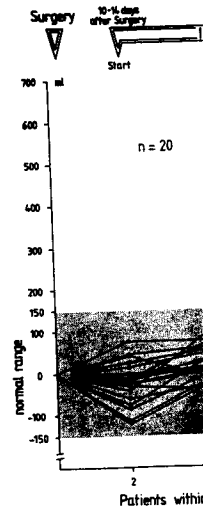
This method is a noninvasive, low-risk procedure for the determination of

lymph kinetics and the severity of lymphostasis (9,10). Useful findings of arm scintigraphic investigations are summarized in *Table 3*. The clearance of the tracer can be monitored using dynamic curves. Our findings confirmed that the 4-hour retention value in the hand is not a useful variable in the determination of lymph dynamics. The static pictures enable the lymph collectors and regional lymph nodes to be assessed qualitatively, and the typical radiomorphological pathological storage pattern was observed.

Brachial volume measurements and arm scintigraphy carried out at the same time on the healthy and mastectomized side showed the following (*Fig. 2*): On the healthy side, the arrival time of the tracer was delayed by more than 16 minutes in 12% of the women. Reduced storage capacity in the axillary region was established in only 1 patient.

In this patient group 14 days after modified radical mastectomy, the arm on the operated side showed delayed lymph transport in 48% of patients, and markedly decreased axillary storage activity in 84%. The mean arm volume compared with the healthy side was only 32ml higher. There was no relationship between the arm volume and the number of lymph nodes removed or the quantitative lymphodynamic findings.

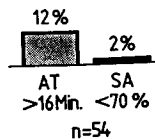
In patients without brachial edema, two years after operation and irradiation, a delayed isotope arrival time was



*Fig. 1. Changes irradiation.*

healthy arm

Arm volume: 1923ml



*Fig. 2. Delayed (SA) using brach*

observed contrary to expectation and a decreased axillary storage activity was seen in 90%. Since the patients do not develop brachial edema, one would have expected more to have normal lymph

ied  
ation

---

19.3 Months  
after Surgery  
and Irradiation  
[n = 200]

---

25%

10%

7%

42%

---

and the severity of lymphoedema. Useful findings of arm volume investigations are summarized in Table 1. The clearance of the lymphoedema is monitored using dynamic lymphoscintigraphy confirmed that the lymphoedema value in the hand is not significantly different from the value in the determination of lymphoedema. The static pictures of lymphoedema which collectors and regional lymphoedema be assessed qualitatively, lymphoedema radiomorphological pathomorphological pattern was observed. lymphoedema volume measurements and lymphoedema carried out at the same lymphoedema healthy and mastectomized lymphoedema following (Fig. 2): On lymphoedema, the arrival time of the lymphoedema is delayed by more than 16 min-lymphoedema the women. Reduced lymphoedema in the axillary region was lymphoedema only 1 patient. lymphoedema patient group 14 days after lymphoedema mastectomy, the arm on lymphoedema the showed delayed lymphoedema lymphoedema 8% of patients, and lymphoedema delayed axillary storage activity-lymphoedema mean arm volume com-lymphoedema healthy side was only lymphoedema here was no relationship lymphoedema volume and the number lymphoedema removed or the quantita-lymphoedema lymphoedema findings. lymphoedema without brachial edema, lymphoedema operation and irradiation, lymphoedema the arrival time was

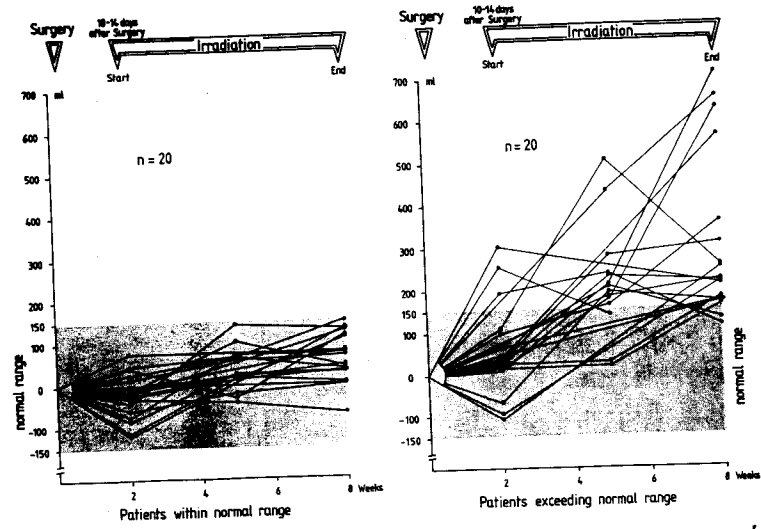


Fig. 1. Changes of arm volume after modified radical mastectomy and irradiation.

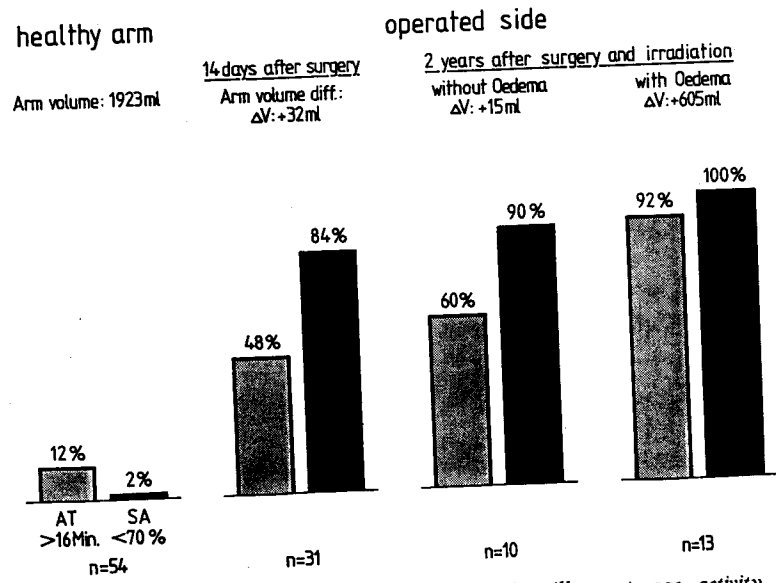


Fig. 2. Delayed arrival time (AT) and decreased axillary storage activity (SA) using brachial lymphoscintigraphy after modified radical mastectomy.

observed contrary to expectations in 60%, and a decreased axillary storage activity was seen in 90%. Since these women did not develop brachial edema after operation, one would have expected many more to have normal lymphoscintigraphic

measurements. A disturbance of axillary lymph drainage was found in almost two-thirds of women who did not have brachial edema which suggests that lymphostasis was compensated for in these individuals by alternative drainage routes.

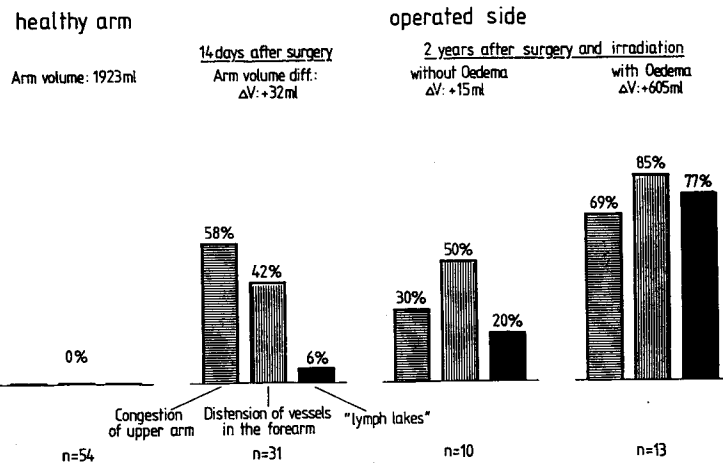


Fig. 3. Storage activities in lymph vessels in the upper arm and forearm at lymphoscintigraphy after modified radical mastectomy.

Table 3

### Aspects of Brachial Lymphoscintigraphy

#### Quantitative:

- Arrival time of tracer
- Storage activity in axillary region
- Amount retained at site of injection

#### Qualitative:

- Radiomorphological assessment of lymph ducts and their pathological storage structure:
  - Congestion in upper arm
  - Distended vessels in forearm
  - Lymph lakes
- Imaging of regional lymph nodes:
  - Axillary
  - Supra-infraclavicular
  - Cubital

In patients with moderate and severe brachial edema, the arrival time was decreased in 92%, and in all patients the axillary storage capacity was reduced or the axilla showed lack of tracer. In these patients, clinical and lymph dynamic investigations revealed the typical picture of "decompensated lymphostasis."

The healthy arm was consistently used as the standard for the radiomorphologic assessment of the lymph ducts in the contralateral arm. As a result of the impairment of lymph drainage, marked retention of tracer was observed

2 weeks after surgery in 58% in the upper arm and 42% in the forearm, and "lymph lakes" were even seen in 6% (Fig. 3). Two years after surgery and irradiation, 30% of the women without brachial edema had lymphostasis of the upper arm and in half the lymphatics in the forearm were slightly distended. "Lymph lakes" were observed in 20% of patients. The static pictures in the women without arm swelling indicated the presence of "compensated lymphostasis" in 30-50%. In these patients, however, it is not clear whether a "lymph lake" indicates that "compensated lymphostasis" is bordering on "decompensation" (Fig. 4,5).

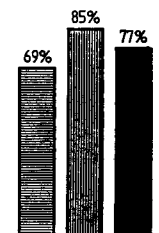
As with the decompensated lymphostasis, patients with severe brachial edema exhibited marked signs of upper arm/forearm lymphostasis in 70-85%. In 77%, leakage of tracer into the "lymph lakes" was observed, often accompanied by dermal backflow (Fig. 5).

In static images, we also assessed the axillary, supraclavicular and infraclavicular lymph nodes (Fig. 6). On the healthy side there was evidence of lymph node retention in all patients in the axillary region and in 20% of patients in the supraclavicular region. Postoperative retention of the tracer was observed in the axillary lymph nodes in 84% of patients. Lymph nodes in the supra-infra-

Fig. 4. Dynamic mastectomy. 1 (region of in images of arm and decrease normal distrib Fig. 5).

clavicular region were d almost 40% probably refl drainage pathways, e.g. lymphatics. In women edema, axillary lymph r onstrable in only 60% t treatment and the num

ery and irradiation  
with Oedema  
 $\Delta V: +605\text{ml}$



n=13

arm and forearm

surgery in 58% in the upper  
1 the forearm, and "lymph  
en seen in 6% (Fig. 3).  
er surgery and irradiation,  
omen without brachial  
phostasis of the upper arm  
: lymphatics in the forearm  
listended. "Lymph lakes"  
in 20% of patients. The  
n the women without arm  
ted the presence of "com-  
hostasis" in 30-50%. In  
however, it is not clear  
nph lake" indicates that  
ymphostasis" is bordering  
ation" (Fig. 4,5).

the decompensated lym-  
ents with severe brachial  
d marked signs of upper  
mphostasis in 70-85%. In  
f tracer into the "lymph  
erved, often accompanied  
flow (Fig. 5).

images, we also assessed  
praclavicular and infraclav-  
odes (Fig. 6). On the  
ere was evidence of lymph  
in all patients in the axil-  
l in 20% of patients in the  
region. Postoperative  
e tracer was observed in  
nph nodes in 84% of pa-  
nodes in the supra-infra-

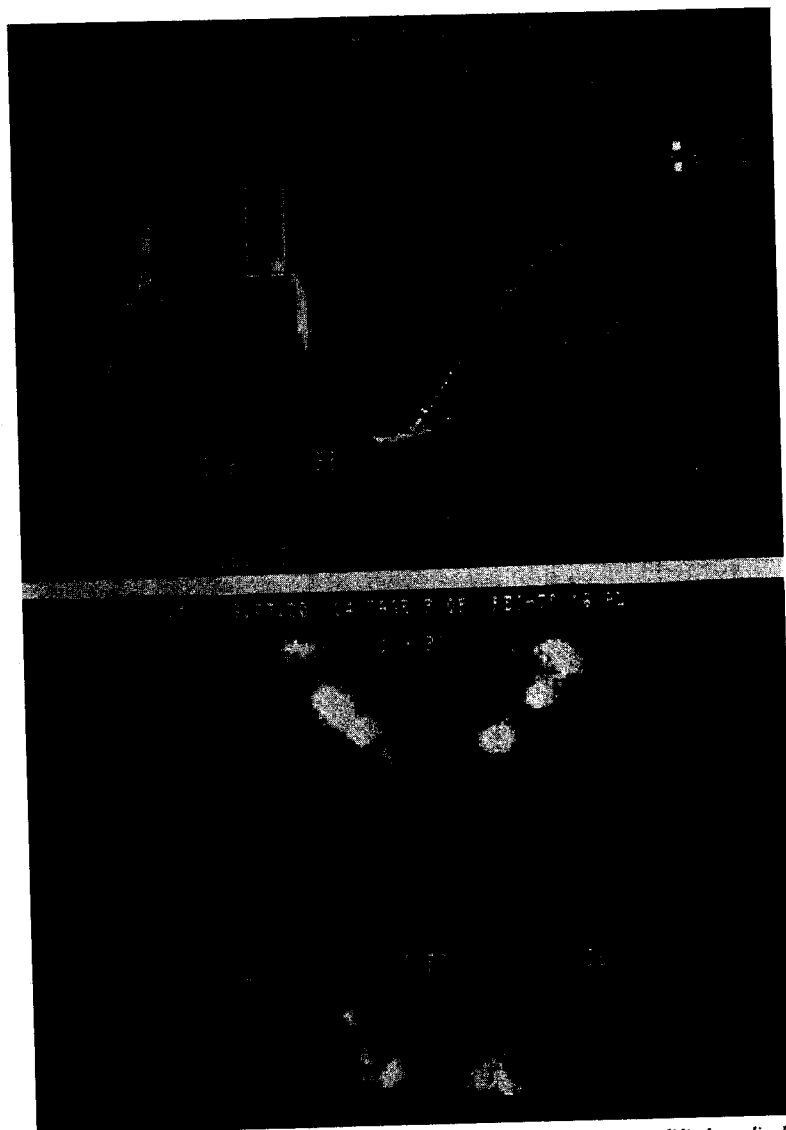


Fig. 4. Dynamic and static lymphoscintigram 14 days after modified radical mastectomy. Note the decreased radioactive uptake in the right axilla (region of interest) during the first hour (above, upper right). Static images of arms (above, upper left) show distension of right arm lymphatics and decreased nodal uptake. Static images of forearms (below) show nearly normal distribution of tracer in lymphatics and orbital nodes (compare with Fig. 5).

clavicular region were demonstrated in almost 40% probably reflecting alternative drainage pathways, e.g., via cephalic lymphatics. In women without brachial edema, axillary lymph nodes were demonstrable in only 60% two years after treatment and the number of patients

with supra/infraclavicular storage remained unchanged.

In the presence of decompensated lymph drainage, lymph nodes were demonstrable in just under one third of the patients in the axillary region and in 23% of the patients in the supra/infraclavicular

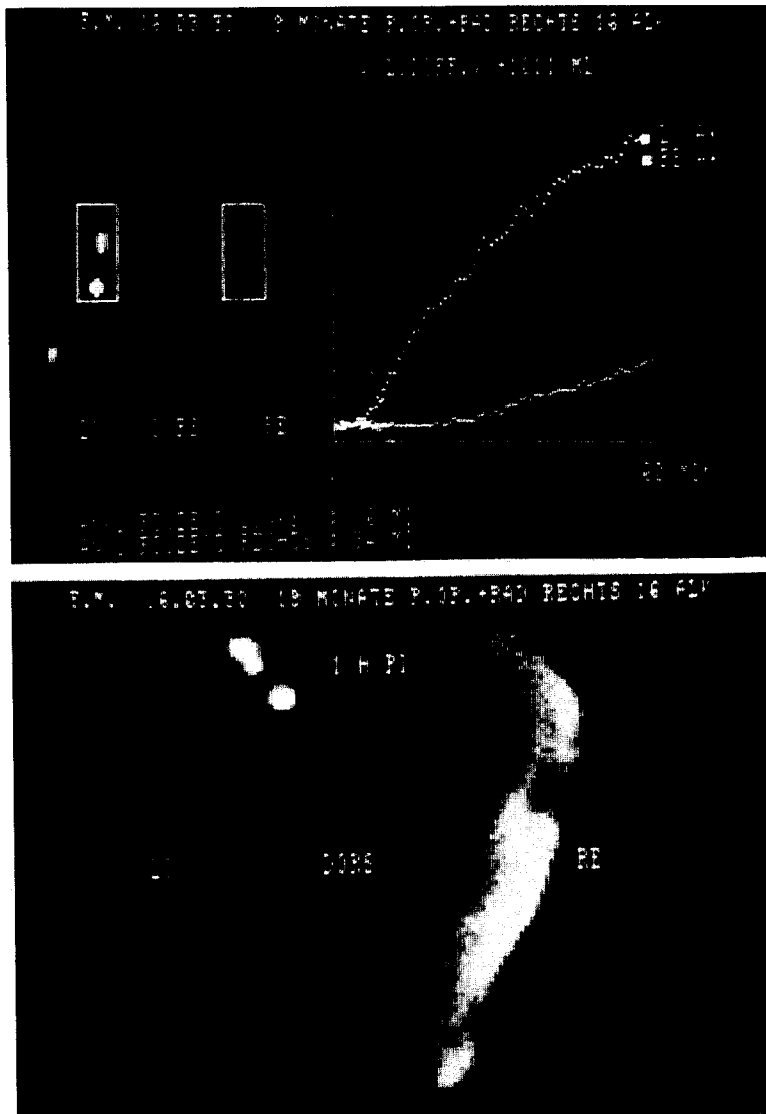


Fig. 5. Dynamic and static lymphoscintigram 19 months after modified radical mastectomy and supplemental irradiation. Tracer transport on the right (RE) is further delayed with paucity of axillary nodal uptake (upper); and moreover, there are now large "lymph lakes" with tracer extravasation ("dermal backflow") in the abnormal forearm (below)(compare with Fig. 4).

region.

Because lymph is drained from the arm via the superficial and deep lymph duct systems, we chose computer tomography to study the epifascial and subfascial volume of distribution in postmastectomy patients (Table 4). Quantitative assessment was performed planimetrically, while the clinical evaluation included the

site of edema in the upper arm and forearm and soft tissue changes.

In the presence of slight brachial swelling, the epifascial area increases slightly in size (Fig. 7). Severe edema simultaneously affects both the epifascial and subfascial compartments. It is noteworthy that the epifascial surface of the upper arm and forearm increased by

healthy arm

Arm volume: 1923ml

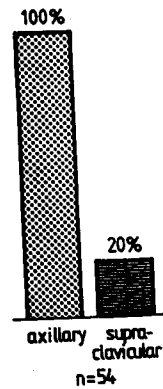


Fig. 6. Detectable lymphoscintigraph

Table 4

Aspects of Computer to Assess Lymph after Mastectomy

Quantitative:

-Planimetric assessment of subfascial areas

Qualitative:

- Radiomorphological characteristics
- Commonest site of edema
- Upper arm - medial
- Forearm - over the
- Tissue changes:
- Thickening of skin
- Widening of lymph
- Formation of lacunae
- tissue
- Dissociation of nodules
- Muscular atrophy
- Increase in cross-sectional

44 and 67% respectively in severe edema. As the volume of fascial region increased, the region sometimes paradoxically even when lymphostasis fluid shift probably resulting in rising pressure in the causing maximum overstretching of the skin and thereby further distending the subfascial compartment

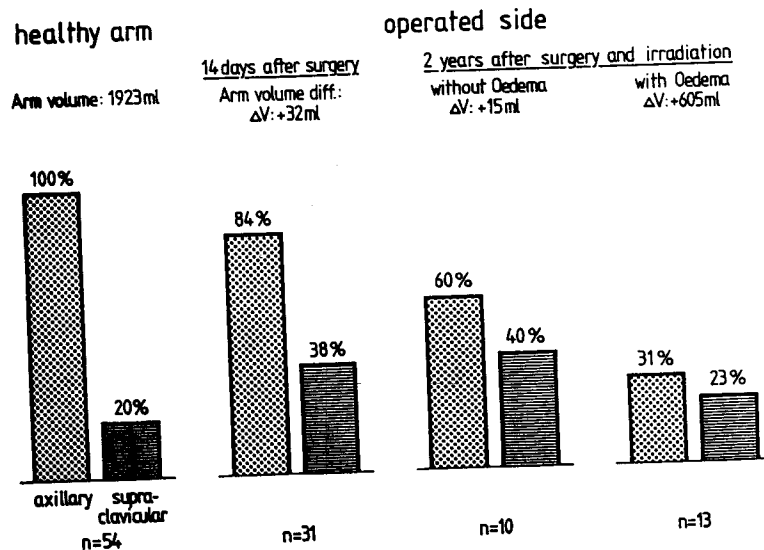


Fig. 6. Detection of axillary and supraclavicular lymph nodes at brachial lymphoscintigraphy after modified radical mastectomy.

Table 4

Aspects of Computer Tomography to Assess Lymphedema after Mastectomy

Quantitative:

-Planimetric assessment of epifascial and subfascial areas

Qualitative:

-Radiomorphological characteristics:

Commonest site of edema:

Upper arm - mediodorsal  
 Forearm - over the ulna

Tissue changes:

Thickening of skin/subcutis  
 Widening of lymph fissures  
 Formation of lacunae with fibrous tissue  
 Dissociation of muscle fiber bundles

Muscular atrophy

Increase in cross-sectional area of vessels

44 and 67% respectively in the presence of severe edema. As the volume of the epifascial region increased, the subfascial region sometimes paradoxically decreased even when lymphostasis was severe. This fluid shift probably resulted from the rising pressure in the epifascial space causing maximum overstretching of the skin and thereby further compression of the subfascial compartment.

Edema usually occurs mediodorsally on the upper arm and over the ulna on the forearm. The typical tissue changes in lymphatic edema are thickening of the skin and subcutis, a distention of lymph fissures and the formation of lacunae with fibrous tissue. Even in the presence of moderate edema, fluid deposits can be identified in the subfascial space both between and in the bundles of muscle fibers. We also observed muscular atrophy with moderate and severe edema of large duration. A clear increase in the cross-sectional area of lymphatics was observed epifascially in all patients with severe arm edema. In extremely severe examples of edema, honeycombing and ring-like patterns of distribution suggest irreversible transformation of the edematous areas into connective-tissue-like structures (Fig. 8) (1,15,8).

DISCUSSION

These investigations used three complementary methods to examine the pathophysiology of brachial edema after mastectomy with and without irradiation. Each method provided different information. The immediate and delayed formation of brachial edema caused by surgical

er modified radi-  
 ort on the right  
 take (upper); and  
 extravasation  
 are with Fig. 4).

the upper arm and fore-  
 sue changes.  
 sence of slight brachial  
 ifascial area increases  
 (Fig. 7). Severe edema  
 ffects both the epifascial  
 compartments. It is  
 the epifascial surface of  
 nd forearm increased by



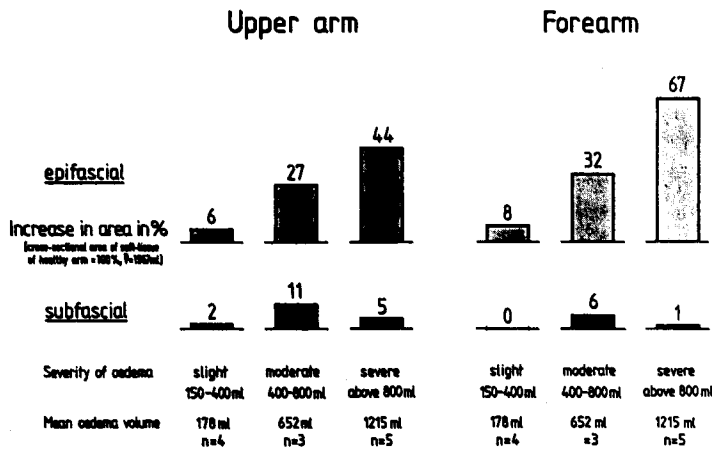


Fig. 7. Changes in cross-sectional area at computer tomography of the upper arm and forearm with different degrees of brachial edema after mastectomy.

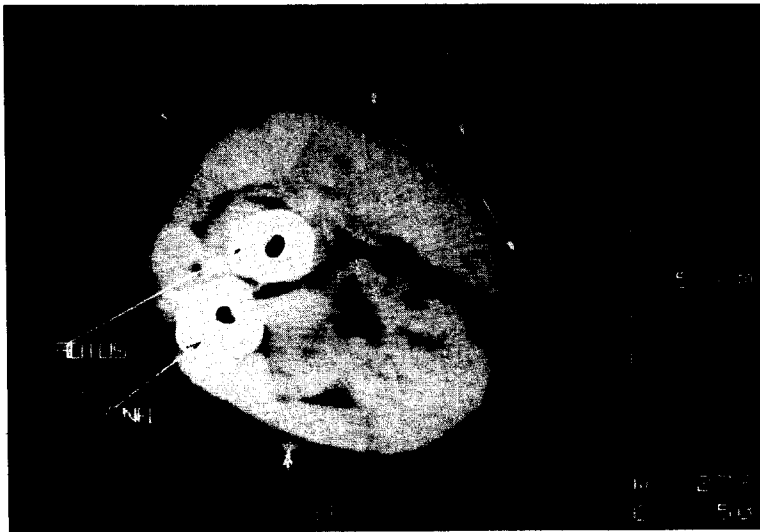

Fig. 8. Computed tomography of forearm in patient with severe lymphedema after modified radical mastectomy and post-operative irradiation. Note the thickened skin and distention of lymphatics in ring-like patterns and honeycomb formation.

and/or radiological damage to the axillary lymph system depended largely on the capacity of the lymph system and its ability to compensate with time (4).

Optoelectronic volumetry enables objective follow-up measurements to be made in clinical practice, and even to

detect slight swelling of the arm. The routine, early identification of brachial swelling is critical in the prognosis of arm lymphedema since early treatment facilitates prompt correction of a disturbed drainage of lymph (7). The present results document that a reduced capa-

city to transport lymph in the axilla caused by surgery is compensated for in more than 50% of patients. Increase of moderate and severe edema occurs in the first treatment. The number of slight arm swelling (which is regarded as not in need of treatment) is still comparatively high at 2 years incidence of subtle and overt edema following the treatment of the breast still proving a challenge.

Although it is time-consuming, noninvasive lymphoscintigraphy reveals functional disturbances in lymph collectors at an early treatment stage. Nonetheless, quantitative and qualitative scintigraphy are fully reviewed. Scintigraphy does not provide information on the individual patient insofar as it does not compensate with alternative drainage. It is noteworthy that lymphedema was compensated for in 50% of the women without lymphadenectomy who underwent lymphoscintigraphy after surgery and irradiation. In patients, however, who had severe edema had the typical signs of lymphedema on scintigraphy: long retention time, absence of storage in axillary nodes, and marked congestion in the lymphatics.

With computer tomography, an expensive procedure, on-line measurements of volume in the epifascial and subfascial tissue compartments can be made. These measurements, however, are only of limited value in the deterioration in lymphatic drainage.

city to transport lymph in the region of the axilla caused by surgery and irradiation is compensated for in only slightly more than 50% of patients. A progressive increase of moderate and severe brachial edema occurs in the first two years after treatment. The number of patients with slight arm swelling (which are commonly regarded as not in need of treatment) is still comparatively high at 25%. Thus, the incidence of subtle and overt brachial edema following the treatment of carcinoma of the breast still presents an ongoing challenge.

Although it is time-consuming and expensive, noninvasive lymphoscintigraphy reveals functional disturbances in lymph kinetics and radiomorphological changes in lymph collectors at an early post-treatment stage. Nonetheless, even if the quantitative and qualitative results of scintigraphy are fully reviewed, this technique does not provide information for the individual patient insofar as the ability of the lymph drainage area to compensate with alternative routes of drainage. It is noteworthy that lymphostasis was compensated for in more than half of the women without brachial swelling who underwent lymphoscintigraphy 2 years after surgery and irradiation. Nearly all patients, however, who manifest brachial edema had the typical signs of decompensation on scintigraphy (delayed arrival time, absence of storage activity in the axillary nodes, and marked signs of congestion in the lymph ducts).

With computer tomography, an expensive procedure, only shifts in the volume in the epifascial and subfascial tissue compartments can be assessed as well as changes in tissue structure. The latter, however, are only evident if the deterioration in lymph transport is far


advanced. This method is not suitable as a routine diagnostic procedure in these patients as it has a low benefit/cost ratio.

## REFERENCES

1. Bruna, J: Diagnostik des Lymphoedems durch die Computertomographie. *Ödem 1* (1986), 117-119, peri-med-Verlag, Erlangen.
2. Coutureau, G, H Weissleder: Statische Lymphszintigraphie. *Der Nuklearmediziner 7* (1984), 301.
3. Fischbach, JU, B Monter, E Goltner: Messungen von Armödemem durch optoelektronische volumetrie. *Phlebol. u. Proktol. 15* (1986), 184.
4. Földi, M: Das Lymphoedem: *Dtsch. Arztebl. 78* (1981), 1813. *Postmastektomie-Lymphoedem: Dtsch. med. Wschr. 107* (1982), 1899.
5. Gamba, JL, PM Silvermann, D Ling, et al: Primary lower extremity lymphedema: CT diagnosis. *Radiology 149* (1983), 218.
6. Göltner, E, JU Fischbach: Eine neue Meßmethode zur Erfassung von Armödemem nach Brustkrebsbehandlung. *Therapiewoche 36* (1986), 218.
7. Göltner, E, JU Fischbach, B Mönter, et al: Objektivierung des Lymphoedems nach Mastektomie. *Dtsch. med. Wschr. 110* (1985), 949.
8. Hadjis, NS, DH Carr, L Banks, et al: The role of CT in the diagnosis of primary lymphedema of the lower limb. *Am. J. Radiology 144* (1985), 361-364.
9. Mostbeck, A, H Partsch, O Lofferer: Erfassung des Lymphtransportes durch die quantitative Isotopenlymphographie. *Ödem 1* (1986), 52, peri-med-Verlag, Erlangen.
10. Weissleder, H: Lymphszintigraphische Untersuchungen beim Armlymphoedem. *Therapiewoche 35* (1985), 2448.
11. Weissleder, H, C Coutureau: Der Aussagewert der dynamischen und statischen Lymphszintigraphie beim Lymphoedem. *Der Nuklearmediziner 7* (1984), 307.

Prof. Dr. E. Göltner  
Department of Gynecology and  
Obstetrics  
Städtische Kliniken  
Lehrkrankenhaus  
D-6400 Fulda  
WEST GERMANY

earm



Category	Number of Patients
Moderate arm swelling	6
Severe arm swelling	1

ography of the  
ial edema after



th severe lym-  
rative irradiation.  
ring-like patterns

swelling of the arm. The identification of brachial edema is crucial in the prognosis of carcinoma since early treatment permits correction of a disturbance of lymph (7). The presence of lymphatic obstruction is a sign that a reduced capacity